

Efficiency of MLS therapy in abarticular rheumatism revealed by digital thermography and visual analog scale.

A. Momanu, A. Csapo

Physiotherapy and Rehabilitation Centre "FIZIOMEDICA" Iasi, Romania

ABSTRACT

A lot of 22 patients with acute pathology soft-tissue injuries (shoulder peri-arthritis, tendinitis, epicondylitis, bursitis), which was divided into two groups. The first group (G1) received treatment with conventional electrotherapy (interferential or diadynamics current, ultrasound) and 100 mW laser. The second group (G2), received conventional therapy electrotherapy and MLS therapy. The aim of this study was to compare the analgesic and anti-inflammatory effect of the MLS laser therapy and the mono-channel laser treatment in abarticular rheumatism, by digital thermography (outlining the local anti-inflammatory effect by the decrease in the cutaneous temperature), soft tissue echography (visualization of tissular modifications) and by clinical methods (the visual analogue pain scale). The decrease of VAS values to 5 or 10 days of treatment is more important for MLS therapy. It is also apparent decrease in the temperature difference between the affected and the healthy area.

INTRODUCTION

Abarticular rheumatism represents the inflammatory suffering of periarticular soft tissues (muscles, tendons, ligaments, bursae). The clinical expression is the stiffness and pain of the affected areas. The causes include physical overstraining, wear, tissular degeneration. The clinical forms are: peri-arthritis, bursitis, tendinitis, myositis, and epicondylitis.

The most frequent form of peri-arthritis is the scapula-humeral peri-arthritis due to the anatomic characteristics of this joint, which provides great mobility. The most frequent causes are the degenerative lesions of tendons (especially those of supraspinatus and biceps), characterized by necrosis, which lead to partial fractures and calcifications. The wearing processes are frequent in people more than 40 years of age, but they are generally clinically masked; in the presence of certain factors (traumatism, exposures to cold and wet conditions), an inflammatory process also occurs, followed by fibrosis. Clinical signs: localized or diffuse pain, suddenly or insidiously installed, emphasized in

movement (abduction is the most painful movement), limitation of movements, muscular contraction, which may generate the blockage of the shoulder.

Bursae are located among tendons, muscles, ligaments and bones, in the areas where tendons and muscles pass by several bone eminences. Their role is to reduce friction between these anatomic structures in movement, smoothing the slide and facilitating the moves. There are 80 bursae on each side of the human body. The bursae inflammation causes bursitis. There are multiple causes that may lead to their occurrence: overstraining (exercising excessive friction forces), vicious positions ("cleaning woman's knee", "policeman's heel"), direct traumatism; some bursitis may represent the manifestation of a systemic disease, such as rheumatoid polyarthritis or gout (in gout, the olecranon and prepatellar bursae are the most frequently affected ones). The clinical symptomatology of bursitis is dominated by pain, which has the following characteristics: it is spontaneous or caused by pain or by the pressure upon the bursa, it is more intense at night, and it may irradiate to the related limb; in the case of superficial bursitis (olecranon bursa, prepatellar bursa), the inflammation generates their tumefaction; the inflammation of the bursae located nearby joints generated a certain degree of joint stiffness. The topographic perspective reveals numerous forms of bursitis. The most frequent and most important locations are at limbs ("goosefoot" bursitis, trochanteric bursitis, prepatellar bursitis - "cleaning woman's bursitis", achilles bursitis, calcaneal bursitis, hallux bursitis, subdeltoid bursitis, olecranon bursitis).

Tendinitis and tenosynovitis represent an inflammation of tendons, of synovial sheath, respectively, covering the muscle tendons. De Quervain tenosynovitis and epicondylitis are the most frequent ones. Tenosynovitis of the short extensor and long abductor muscles of the thumb

is also named De Quervain disease. Patients find it difficult to hold objects in their hand, and they cannot lift weights. Lateral epicondylitis frequently occurs at tennis players, due to the degenerative modifications of the tendon from the common extensor of the fingers and of the short radial extensor muscle of the carpus. Medial epicondylitis occurs in golf players and it affects the radial flexor muscle of the carpus, which makes the hand flexion against some resistance become painful.

As all these affections of the periarticular soft tissues are associated to pain and, sometimes, to the limitation of the joint mobility, they may lead to an incapacity for work; moreover, as there are numerous cases which are caused by professional overstraining, their treatment must be prompt and intense. The therapeutic behaviour includes the administration of NSAD, general and local corticotherapy or physiotherapy in many forms (electrotherapy, ultrasounds, short waves, laser therapy), but the symptomatology is often protracted and rebellious to treatment.

Ever since it was discovered, the LASER has permanently extended its application field. Since 1970, laser has been successfully used, first of all in surgery, and then in medical specializations as well. Controlled clinical studies of LLLT effectiveness in abarticular rheumatism (especially in shoulder periarthritis) showed different and sometime contradictory results. Some studies have demonstrated that low-level laser therapy is either totally ineffective in treating the scapular-humeral periarthritis [1-5] and the epicondylitis [4,6-7], but other studies proved higher efficiency compared with other therapeutic means when recommended dosages are used.[8-12] The lasers used in physiotherapy have several common biological effects, but also particular effects, depending on the power and the type of the source.

The anti-inflammatory and anti-edematous effect. Lasers may influence the inflammation mechanisms at different levels. First of all, an active hyperemia is produced by the increased diameter and the decreased permeability of lymphatic vessels and capillaries, which generates a washing effect on the inflammatory substances (histamine, bradykinin, cytokine and lymphokine). Vasodilation increases the intake of oxygen and nutritive substances, an essential process in the repairing of the injured tissues. The laser stabilizes the membrane of the mastocytes (histamine producers) and stimulates phagocytes, which will eventually remove the harmful substances.

The analgesic effect. This effect is generated by several mechanisms. First of all, the laser induces the blockage of the action potential at the nociceptor level by the modification of the axonal membrane permeability. Then, the active hyperemia caused by heat and by the photochemical reactions encourages the drainage of the algogenic substances, eliminating the cause of the pain sensation. Pulsed emission lasers, especially the low-frequency ones, act on pain modulation by means of the big, myelinated fibers, according to the "gate" theory. [13] The laser eventually generates the production of morphinomimetic substances (endorphins and enkephalins), which have an analgesic action (a mechanism that is also proven by the emphasized increase in the urinary excretion of a serotonin degradation product - 5-Hydroxyindoleacetic acid, which precedes the amelioration of pain by several days). [14]

The biostimulation effect of Laser increases the ATP production, a phenomenon that encourages the cellular energetic processes. Mitochondria are the cellular organelle where these processes are developed, but the mediator between photons and the activation of biological processes has not been identified yet. Laser light may encourage cellular replication and RNA and proteins synthesis (collagen,

for instance), facilitating the repairing processes. [13]

In comparison to the classical laser therapy, the MLS therapy has several special characteristics: it combines laser emissions with two wavelengths (808 and 905 nm), one in the continuous system (808 nm, with a maximum power of 1W), and the other one in a pulsed system (905 nm, with a maximum power of 25 W). The advantage of this combination consists in better penetrability and in the possibility of increasing the emitted energy. Therefore, the pulsing system combines the stimulating effect on microcirculation with the advantage of an increased top power, but they have a low average energy, and the combination to a continuous laser wave secures an appropriate energetic intake. The synchronizing of the two wavelengths may transfer the energy towards the cellular sublayer in a more efficient manner than the emission of a single component. Thus, the MLS impulse has bigger antiphlogistic, bio-stimulating and analgesic effects than a continuous emission or a pulsed one, used separately or in combination, but unsynchronized. Enjoying the advantage of a bigger divergence of the diodes irradiation cones, the multidiode laser may have a spot of big dimensions - 50 mm. its wavelength and the energetic transfer method in relation to time.

MLS therapy creates the conditions for the achievement of numerous therapeutic effects, as it has an anti-inflammatory, anti-edematous, and analgetic action, which eventually leads to rapid ameliorations.

Starting from these theoretical premises, we have monitored the evolution under a complex physiotherapy treatment of a lot of patients with abarticular rheumatism, in order to compare the analgetic and anti-inflammatory effects of MLS laser therapy with traditional laser therapy. In order to monitor the analgetic effects, we have used the visual analogue scale of pain (VAS). As laser therapy generates an analgetic effect both by

direct action at the nociceptor level, and by the production of morphinomimetic substances, not merely as a consequence of the local anti-inflammatory effect, VAS is not appropriate to monitor the anti-inflammatory effects, and have therefore used a parameter which directly reflects local inflammation, that is the cutaneous temperature measured by digital thermography.

Digital thermography is a non-invasive physiological test. It is a valuable investigation that may provide medical alerts in relation to the modifications indicating a precocious stage of breast cancer, or it may be used in the exploration of unknown origin pain. It is also useful in the monitoring of treatment evolution for numerous diseases.

In 1965, Gershon-Cohen, a radiologist and researcher from Albert Einstein Medical Center, introduced thermography in USA. Ever since the last period of the 70s, numerous medical centres and independent clinics have used this exploration method on thousands of patients. In 1982, FDA (Food and Drugs Administration) approved thermography as a screening method for breast cancer, and, since 1990, it has been acknowledged as a diagnostic instrument by the American Academy of Physical Medicine and Rehabilitation. [15]

In the case of periarticular soft tissues affections, thermography may reveal the local vasomotor and inflammatory reaction by increased local temperatures and/or by the modification of the cutaneous heat map, as it is well-known that the heat symmetry principle is normally observed. [16]

Since it is a non-invasive method, the investigation may be repeated at any time throughout the treatment in order to monitor local modifications of temperature, which follow the evolution of the local inflammatory process.

MATERIAL AND METHODS

We have studied a lot of 22 patients presenting an acute abarticular pathology (scapulohumeral peri-arthritis, tendinitis, epicondylitis, and bursitis) (table I) which was divided in two parts. The first group (G1) made of 12 patients (8 women, 4 men) with an average age of 50,7 years received a conventional electrotherapy treatment (interferential and diadynamic currents, ultrasound) and 100 mW LASER. The second group (G2) made of 10 patients (6 women, 4 men) with an average age of 45,8 benefited from conventional electrotherapy and MLS therapy (table II).

TABLE I. DISTRIBUTION TYPES OF THE DISEASES STUDIED WITHIN BOTH GROUPS.

	G1	G2
Shoulder peri-arthritis	6	6
Epicondylitis	3	2
Quervaine's tenosynovitis	1	1
Prepatellar bursitis/housemaid's knee	2	1

TABLE II. DEMOGRAPHICAL DATA

	G1	G2
Mean age	50,7	45,8
Sex (F/M)	8/4	6/4

Both groups included all types of studied pathology, with a balanced distribution (fig 1. and fig. 2).

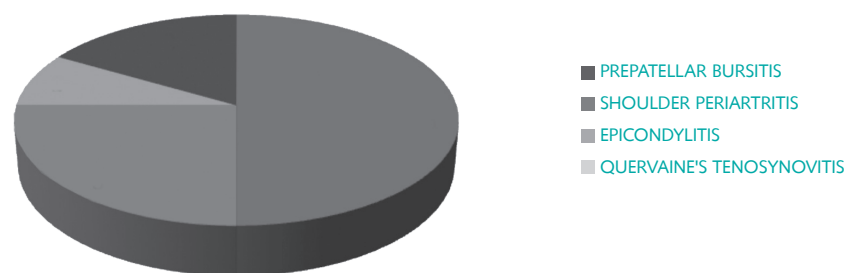


Fig. 1. Distribution types of the diseases studied within the group treated with the classic laser therapy

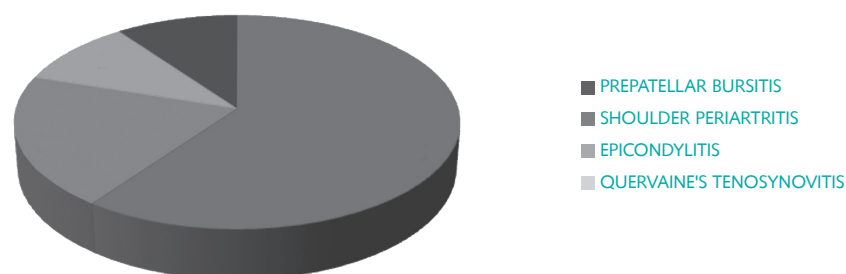


Fig. 2. Distribution types of the diseases studied within the group treated with the MLS laser therapy

METHODOLOGY

The patients received a physiotherapy session per day for 10 days. The first group was applied a laser therapy (830 nm wavelength) by non-contact technique with a 100 mW probe, in dosages of 6 J/cm², by punctiform irradiation in 6-10 points. In order to treat the second group, we have used all the preset programs of the MLS M6 device, by scanning the affected area (with the 3300 mW probe) and after that the irradiation of the painful points (with the 1500 mW probe). The evolution of pain through the visual analogue scale (VAS) was monitored in both groups; the instant pain, the pain upon palpation and the pain upon mobilization initially, after 5, 10 days of treatment and 30 days after the termination of treatment was assessed; digital thermography and soft parts ultrasound were performed before starting the treatment and after the 10 session cure.

The thermo graphical determinations have been performed with a Flir B60 termocamera under controlled measurement conditions (22- 23 C room temperature, the patient needs 15 minutes for room temperature accommodation) and aimed to determine the modification of the temperature difference between the treated area and the contra lateral unaffected area.

Inclusion criteria: suggestive symptomatology for abarticular rheumatism with less than 3 weeks debut and the existence of ultrasound modifications.

Exclusion criteria: AINS previous or concomitant treatment, local/general corticosteroid therapy or the presence of some lesions in which the laser therapy is contraindicated: neoplasia, infectious cutaneous lesions, bleeding tendency body surfaces.

RESULTS

In both groups studied, was observed reduction of spontaneous pain (fig. 3), of pain on palpation (fig. 4) and of pain during mobilization (fig. 5), lower VAS values being more important in the MLS

therapy, the differences between the two groups being statistically significant in all moments ($p < 0.005$).

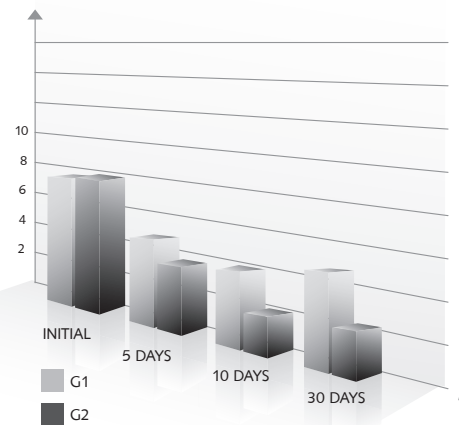


Fig. 3. Evolution of spontaneous pain - VAS score

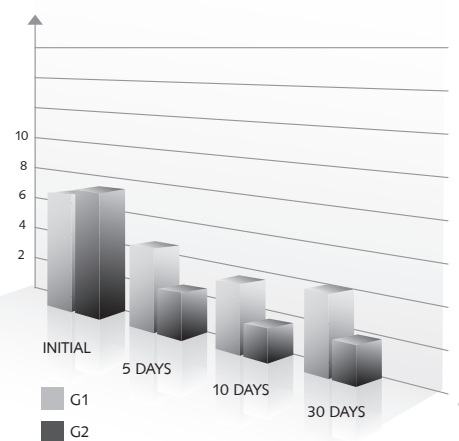


Fig. 4. Evolution of pain at palpation - VAS score

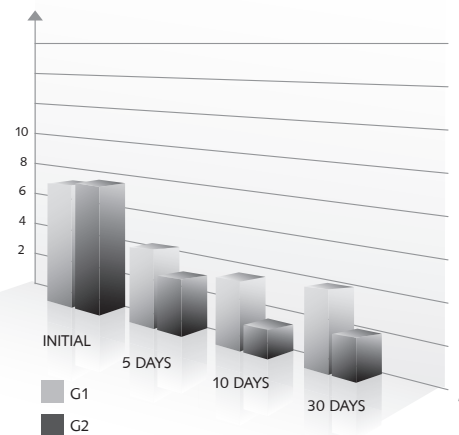


Fig. 5. Evolution of Pain during mobilization - VAS score

Also within both groups, the difference between the local temperature of the affected area and the contra lateral stimulated area has dropped, the reduction being more important in the group treated with the MLS laser therapy ($p = 0,034$).

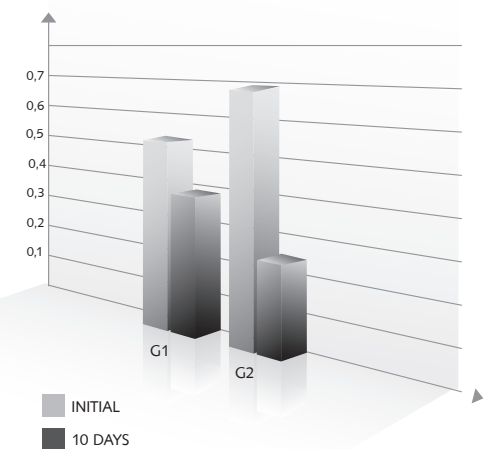


Fig. 6. Evolution of skin temperature difference ($p = 0,034$)

DISCUSSIONS

The results from our study may support the importance of MLS therapy for analgesic and anti-inflammatory effects in patients with abarticular rheumatism over classical laser therapy. In this kind of pathology, pain control represents one of the principal tasks in order to get over acute phases. In this study, patients enrolled in the MLS therapy group reported very early (in some cases even after 2-3 treatments) a significant pain reduction and increased mobility of affected joints.

The results of this study also demonstrate anti-inflammatory effect of MLS therapy by lowering the local temperature measured by digital thermography.

Of the studied cases, an impressive evolution of the issued pursued, both pain and local inflammation shown through determining temperature by digital infrared thermography, was found in a prepatellar bursitis in which clinical symptoms improved after the first treatment session

and the temperature difference between the affected knee and the healthy one reduced from 3.8 °C to 0.3°C at the end of 10 treatment sessions (fig. 7). Could also be ascertained by ultrasonography of soft tissue the reduction of the amount of fluid from the bursa prepatellar.

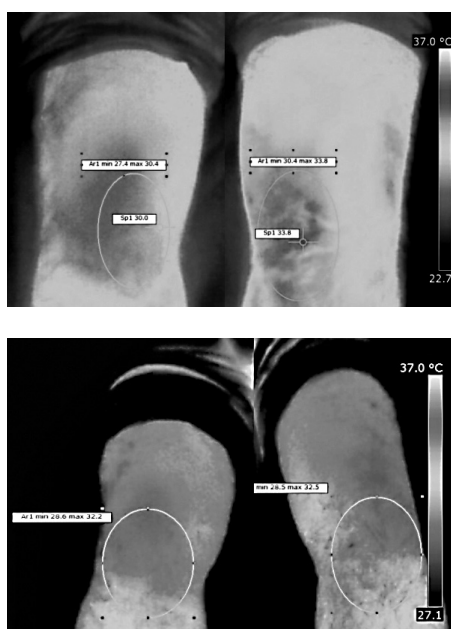


Fig. 7. Thermographic aspect of prepatellar bursitis before and after treatment

Unlike other forms of physiotherapy (including classical laser therapy), which according to literature data are not very effective in treating abarticular rheumatism, MLS therapy works quickly and efficiently in this type of pathology, reducing pain and functional impotence after a few treatment sessions. Because of the analgesic and anti-inflammatory effect MLS therapy may represent an alternative at administration of anti-inflammatory medications (corticosteroids or NSAIDs) and it has the advantage of fewer adverse effects and a much greater persistence for analgesic and anti-inflammatory effect over time.

CONCLUSIONS

- MLS therapy leads to a faster reduction of pain symptoms.
- In case of periarticular soft tissue diseases, the anti-inflammatory effect of MLS laser therapy may be confirmed through the reduction of temperature differences compared with the healthy contra lateral area.
- The analgetic effect obtained with MLS therapy is long lasting.

REFERENCES

1. Bjordal JM. Review Conclusion For Low-Level Laser Therapy In Shoulder Impingement Syndrome Appears To Be Sensitive To Alternative Interpretations Of Trial Results. *J Rehabil Med.* 2010 Jul;42(7):700-1; Author Reply 1-2.
2. Brox JI, Bohmer AS, Ljunggren AE, Staff PH. [Treatment Of Chronic Shoulder Tendinitis]. *Tidsskr Nor Laegeforen.* 1994 Feb 20;114(5):575-7.
3. Dogan SK, Ay S, Evcik D. The Effectiveness Of Low Laser Therapy In Subacromial Impingement Syndrome: A Randomized Placebo Controlled Double-Blind Prospective Study. *Clinics (Sao Paulo).* 2010;65(10):1019-22.
4. Longo L, Simunovic Z, Postiglione M. Laser Therapy For Fibromyositic Rheumatisms. *J Clin Laser Med Surg.* 1997;15(5):217-20.
5. Michener LA, Walsworth MK, Burnet EN. Effectiveness Of Rehabilitation For Patients With Subacromial Impingement Syndrome: A Systematic Review. *J Hand Ther.* 2004 Apr-Jun;17(2):152-64.
6. Stasinopoulos D, Stasinopoulos I, Pantelis M, Stasinopoulou K. Comparing The Effects Of Exercise Program And Low-Level Laser Therapy With Exercise Program And Polarized Polychromatic Non-Coherent Light (Bioptron Light) On The Treatment Of Lateral Elbow Tendinopathy. *Photomed Laser Surg.* 2009 Jun;27(3):513-20.
7. Huang HH, Qureshi AA, Biundo JJ, Jr. Sports And Other Soft Tissue Injuries, Tendinitis, Bursitis, And Occupation-Related Syndromes. *Curr Opin Rheumatol.* 2000 Mar;12(2):150-4.
8. Chang WD, Wu JH, Yang WJ, Jiang JA. Therapeutic Effects Of Low-Level Laser On Lateral Epicondylitis From Differential Interventions Of Chinese-Western Medicine: Systematic Review. *Photomed Laser Surg.* 2010 Jun;28(3):327-36.
9. Emanet SK, Altan LI, Yurtkuran M. Investigation Of The Effect Of Gaas Laser Therapy On Lateral Epicondylitis. *Photomed Laser Surg.* 2010 Jun;28(3):397-403.
10. Tumilty S, Munn J, Abbott JH, Mcdonough S, Hurley DA, Baxter GD. Laser Therapy In The Treatment Of Achilles Tendinopathy: A Pilot Study. *Photomed Laser Surg.* 2008 Feb;26(1):25-30.
11. Tumilty S, Munn J, Mcdonough S, Hurley DA, Basford JR, Baxter GD. Low Level Laser Treatment Of Tendinopathy: A Systematic Review With Meta-Analysis. *Photomed Laser Surg.* 2010 Feb;28(1):3-16.
12. Oken O, Kahraman Y, Ayhan F, Canpolat S, Yorgancioglu ZR, Oken OF. The Short-Term Efficacy Of Laser, Brace, And Ultrasound Treatment In Lateral Epicondylitis: A Prospective, Randomized, Controlled Trial. *J Hand Ther.* 2008 Jan-Mar;21(1):63-7; Quiz 8.
13. Zati A. *Laser Therapy In Medicine.* Torino: Edizioni Minerva Medica; 2008.
14. Smith KC. *The Photo Biological Basis Of Low Level Laser Radiation Therapy.* Www.lindsaylaser.com [Serial On The Internet]. 1991.
15. Nicholas A. Diakides JDB. *Medical Infrared Imaging.* Boca Raton: Taylor Francis Group; 2007.
16. Jeffrey M. Cohen MHML. *Rehabilitation Medicine And Thermography.* Morrisville, US: Impress Publications; 2008.