

A measure of post-operative satisfaction after application of Mphi therapeutic laser for pain management in patients with surgical extraction of impacted third molars.

N. Doan^{1,2,3}, L. Nguyen-Pham¹, S. Cokim¹

¹School of Dentistry and ²Department of Biomedical Engineering the University of Queensland, Brisbane, Queensland, Australia

³Private practice, Brisbane, Queensland, Australia

ABSTRACT

This study aim to assess the efficacy of a MLS® Mphi therapeutic laser as an adjunct management of postoperative pain, swelling, and trismus related the surgical extraction of impacted third molars using visual analogue scale (VAS) and satisfaction outcome measure. A cohort of 42 impacted wisdom patients, each underwent surgical extraction of 4 extractions under local anesthetic, were selected for a double-blind, randomized, controlled clinical trial. The two groups of patients were divided into control and study group, each of 21 patients, match my age and sex. Immediately after the extraction procedure, the experimental group received one off 1.27 J/cm² of energy density intraorally using Mphi laser while the control

group received sham radiation. The degree of postoperative pain, swelling, trismus, and dry socket was registered for both groups at day one, day 7 (one week) and day 28 (4 weeks). Only those normal patients with 4 impacted wisdom teeth required flap approach, and had complete clinical data were included in this study. Using visual analogue scale (VAS = 0 to 10), the study group revealed to have less: pain, swelling, bleeding and speech impairment and had better overall satisfaction at one day and one week than the control counterpart (*P<0.05). No significant difference in pain at 1 months. The study group showed a less dry socket than the control group without statistical significance. All participants in the both groups required analgesics, however,

the study group required less pain killer than the control group between day one to day seven. At one week, the study group had less moderate trismus and more mild trismus compare to the control group (P<0.05). The application of ASA Mphi laser in the postoperative management of pain in surgical wisdom teeth extraction statistically produced early stage of satisfaction as well as reduced postoperative pain, swelling, bleeding, speech impairment, analgesics use and trismus.

INTRODUCTION

Surgical removal of impacted lower third molars is the most common oral surgery procedure. In spite of better and innovative surgical technology post-surgical complications are still happening. Trauma related inflammation is the main feature associate in most of wisdom teeth extractions couple with pain, swelling, trismus and dry socket. Therefore, management of these complications is of paramount importance to ensure superior outcomes and better patients' satisfaction. The worse post-operative pain most commonly occurs around 3 to 5 hours after surgery, especially, when anesthetics wear off. This type of pain normally persists for another 2 to 3 days, and gradually reduce its intensity toward day 7, and is commonly managed by analgesia such as NSAID while therapeutic application of LLLT has received varied results [1]. Currently there is an innovative method for control of post-operative complications in impacted wisdom tooth extractions through the application of Multiwave-Locked System laser such as Mphi laser. The unique feature of MLS® Laser Therapy is the patented wave technology, combining dual wavelengths and both continuous (808 nm enhanced anti-inflammatory and anti-edema effects) and pulsed (905 nm enhance analgesic effects) waves, making it an efficient laser for treating pain and inflammation, especially, in post-operative dental extraction pain [2]. Mphi laser has many therapeutic indications: sprains, muscle tears, tendinitis,

brachial neuralgia, craniofacial pain, bursitis, lumbago, arthritis, articular pain, edema, and hematoma. MLS® Laser Therapy exert its bio-stimulation effects through its anti-inflammatory and analgesic properties of the 808 nm and 905 nm emissions of the laser [2]. These bio-stimulation effects are very beneficial in management of complications such as pain in wisdom teeth extraction.

Research on LLLT is extensive, to date more than 4,500 articles listed on PubMed on LLLT and over than 1,480 papers discussed pain associated with wisdom teeth extraction. Systemic review on the application of LLLT in pain management and wisdom teeth extractions [1] showed mixed results due to multiple inconsistencies in classification of wavelengths, outcome measures, study methods, recording techniques, degree of wisdom teeth impaction, and duration of surgery.

The marginal benefit of LLLT is of many folds less time taken for quality tissue repair and this is accomplished through a surge of microcirculation in the irradiated area, which consecutively nourish tissue while reducing edema by relieving the equilibrium of hydrostatic filtration and absorption pressures [3].

Mphi MLS® laser provides a new spectrum for research as it is a combined and synchronous wavelength technology. Study on the use of Mphi laser on treatment of craniofacial pain showed promising results [2, 4].

Satisfaction is one of the outcome measure used in this study. It may be considered as a way to quantify patients' experiences at the conclusion of a treatment with emphasis on patients' understanding, viewpoints and assessment. Satisfaction in this study was recorded as the proportion of happiness at the end of the procedure [5]. To determine patient satisfaction, the study uses McGill questionnaire on a visual analogue scale (VAS) [6].

Visual Analogue Scale (VAS) was also used to define patients' post-operative pain [5].

A common post wisdom teeth extraction complication is dry socket or alveolar osteitis.

Dry socket occurs more often in lower more wisdom teeth. The complaint has usually been depicted by disintegrated or impeded recovery accompanying with disintegration or displacement of the blood clot in the healing socket. A typical feature of dry socket is a lasting and burning pain sensation in and around the extraction location around 3 to 7 day after the surgical extraction that is not simply alleviated by analgesics. As Mphi laser has a bio-stimulatory and analgesic property, it will be interesting to see its effect on alveolar osteitis prevalence in this study.

This study aim to assess the efficacy of a MLS® Mphi therapeutic laser as an adjunct management of postoperative pain, swelling, bleeding, speech impairment, and trismus related to surgical extraction of impacted third molars using visual analogue scale (VAS) and satisfaction outcome measure.

MATERIALS AND METHODS

The study was conducted in a private location using a double-blind, randomized, controlled clinical trial using Mphi laser as an adjunct post-operative management. The study group consisted of 21 women and 21 men with mean age of 19.0 (+12.7) with age range from 17-25 years of age. Patients were recruited from a private dental clinic in Brisbane Queensland. The protocols for laser treatment were identical for all members of a same study group. The screening clinical assessment to select patients consisted of clinical exam with the use of intra-oral camera, Joint Vibration Analysis (JVA), Cone Beam Computed Tomography (CBCT) or Orthopantograms. All selected patients must have four impacted wisdom teeth of similar degree of impaction as confirmed in clinical screening assessment.

A cohort of 42 impacted wisdom patients underwent surgical extraction of 4 impacted wisdom extraction under local anesthetic were selected for a double-blind, randomized, controlled clinical trial using Mphi laser as an adjunct post-operative management. Neither the patients nor the operator knew which group the patients

belong to. The two groups of patients were randomly divided into control and study group, each of 21 patients, match by age and sex.

The laser therapy was delivered using a Multiwave-Locked System (MLS®) a NIR laser (model Mphi, ASA laser, Vicenza, Italy) which is considerably distinctive from other laser supply systems: it mixes and synchronizes a pulsed emission at 905 nm and a continuous split emission at 808 nm wavelength with output power up to 1.1W - Peak Power 25W.

MLS® Mphi laser therapy was used for the study group with the following protocols: upper and lower wisdom teeth region- 16 seconds for each extraction site at an intensity of 25% and a frequency of 1500 Hz, time used for each application is 4 seconds, and dosage of 1.27 J/cm² at 4 locations buccal, lingual, distal and occlusal aspect of the extraction sites. Total of 2.5 J applied (Figure 1). The control group received sham radiation and standard management. The degree of postoperative pain, swelling, and trismus was registered for both groups at day one, day 7 (one week) and day 28 (4 weeks) by the same two reviewers. Only those patients with complete clinical data were included in this study.

A. Visual Analogue Scale (VAS) assessment of Post-operative Pain

To establish patient satisfaction, the study assign McGill questionnaire on a visual analogue scale (VAS) ranges from 1 to 10 of which 1 as having no pain and 10 is the worst pain (Fig. 2).

B. Measures of Post-operative Satisfaction

The patients were requested to document their overall satisfaction on sensation of discomfort on a visual-analogue-scale with 0% being totally unsatisfied and 100% being completely satisfied (Fig.3). The VAS scores were recorded for both sides at day one, day seven (one week), day 28 (one month). The VAS scores attained were evaluated for statistical significance.

C. Prevalence of dry socket

When the patients of the two study groups returned at day 7 for review or comeback earlier if dry socket pain was severe then the patient will be registered on the dry socket list.

D. OraStretch® ROM scales to evaluate trismus

Trismus is one of the common complication after wisdom teeth extraction. To quantify trismus this study employed OraStretch® ROM vertical scales. The OraStretch® ROM scales were exclusively devised for patients with sternly restricted openings. The elongated ruler design permit for measurement of the minutest openings as low as 3mm. Here trismus is classified into 3 categories: severe if maximal opening is less than or equal to 15 mm; moderate if it is ≤ 25 mm; and mild if it is ≤35 mm. Any vertical opening ≥35 mm is considered normal.

E. Statistical analysis

One way analysis of variance was performed for statistical significance.

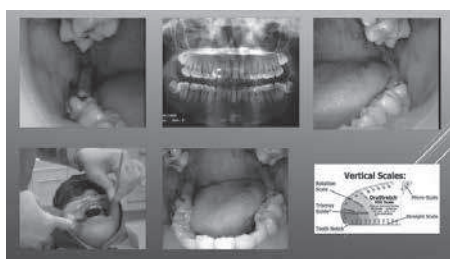


Figure 1: Views of a patient after four wisdom teeth extractions then Mphi laser treatment at extraction sites. The OraStretch scales were used to measure trismus. (From CranioRehab.com)

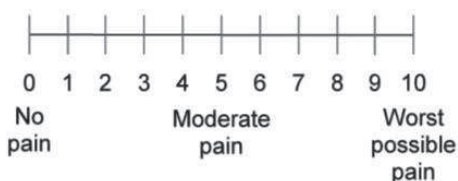


Figure 2: Pain assessment using Visual Analogue Scale

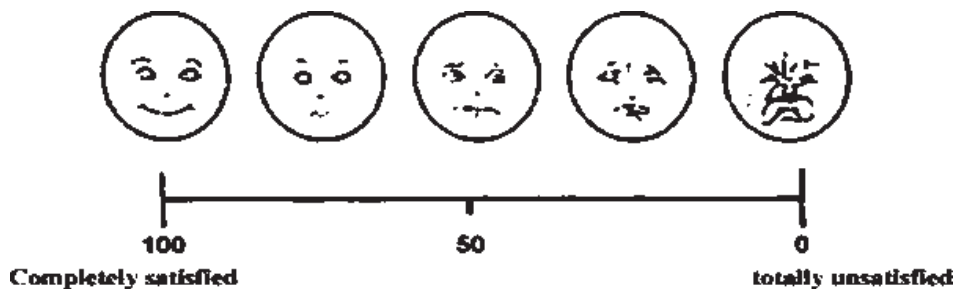


Figure 3: A measure of overall satisfaction

RESULTS

From all the recruited dental patients at a private dental practice, a total of 42 patients 10 males and 11 females of similar age range having 168 extracted wisdom of similar degree of impaction were recorded. All selected patients had the procedure done under local anesthetics. Of 42 patients treated, all patients had flap raised on every tooth extracted. All the extracted sockets were closed using 3/0 resorbable suture, of which none required scheduled removal though some patients might had ask to trim part of their suture to reduce irritation to lips and tongue. No patients failed to return for review at one week and one month.

Using *visual analogue scale* (VAS=0 to 10), study group had less: pain, swelling, bleeding, speech impairment, less days of taking analgesics and had better overall satisfaction at day one and week one than the control counterpart [Fig. 4, (*P<0.05)]. The experienced pain was significantly less in the study group compared to the control group with [5.7 (±1.75) vs 8.9 (±2.83) (*P<0.05)].

Swelling was significantly less in the study group compared to the control group with [5.4 (±1.35) vs 9.3 (±2.37) (*P<0.05)]. Bleeding was significantly less in the study group compared to the control group with [5.4 (±1.35) vs 7.8 (±1.64) (*P<0.05)]. Speech impairment was significantly less in the study group compared to the control

group with [6.5 (±1.78) vs 3.1 (±1.26) (*P<0.05)].

Days of taking analgesics was significantly less in the study group compared to the control group with [3.4 (±0.43) vs 5.8 (±0.23)]

Compare the control vs study group, percentage (%) of Overall Satisfactions were statistically significant at 1 day [(52.5 (±8.43) vs 94.5 (±7.35), *P<0.05) and 1 week [61.5 (±17.34) vs 94.1 (±11.12), *P<0.05] but not at 1 month [94.1 (±11.12) vs 93.2 (±9.76)].

Though there were two female patients in the control group developed dry socket. However, the cases were too small to have any statistical significance.

At one week, the study group had less moderate trismus [(38.1(±10.79) vs 66.7(±19.51) and more mild trismus (61.9 (±19.51) vs 23.8 (±10.75) *P<0.05] compare to the control group. No difference at the degree of pain at 1 month (P>0.05). [Fig. 4].

		Control group Sham laser treated	Test group MLS® laser treated	Overall results
Number of wisdom teeth extracted		21x4	21x4	168
Number of patients failed to return for review		0	0	0
Extraction method		Surgical with flap	Surgical with flap	
Type of analgesia		Local anesthetics	Local anesthetics	Local anesthetics
Prevalence of dry socket (1 week)		2(2.4%)	0.0%	2.4%
Visual Analogue Scale (0 = lowest and 10= highest)	Pain	8.9 (±2.83)*	5.7 (±1.75)*	7.6(±2.29)
	Swelling	9.3 (±2.37)*	5.8 (±1.92)*	7.6 (±2.15)
	Bleeding	7.8 (±1.64)*	5.4 (±1.35)*	6.6 (±1.50)
	Speech impairment	6.5 (±1.78)*	3.1 (±1.26)*	4.9(±1.22)
Days taking analgesics		5.8 (±0.23)*	3.4 (±0.43)*	4.2 (±0.33)
Percentage (%) of Overall Satisfaction (Visual Analogue Scale 0 = lowest and 100 = highest)	1 day	52.5 (±8.43)*	94.5 (±7.35)*	77.8(±7.89)
	1 week	61.5 (±17.34)*	94.1 (±11.12)*	77.8 (±14.28)
	1 month	89.9 (±11.8)	93.2 (±9.76)	89.55 (±10.78)
Trismus measurement using OraStretch® Vertical ROM scales (mm): Severe≤15 mm, Moderate≤25mm, Mild≤15mm	Day 1	0	0	0
	Week 1			
	Severe	9.5 (±8.82)	0	4. (±8.82)
	Moderate	66.7(±19.51)*	38.1 (±10.79)*	52.3 (±14.62)
	Mild	23.8 (±10.75)*	61.9 (±19.51)*	42.9 (±15.71)
	1 Month			
	Severe	0	0	0
	Moderate	0	0	0
	Mild	9.5 (±1.5)	0	4.7(±1.81)

Figure 4: Overall results

Statistical significance: *P<0.05

DISCUSSION

This study has showed that application of Mphi laser in wisdom teeth extractions is a minimal invasive novel technique that can deliver a fairly good outcomes in compared with traditional care approaches. It has also strengthened the notion that the uses of MLS[®] laser can give a foreseeable result with notable efficiency and efficacy in oral surgery such as those seen in surgical wisdom teeth extraction.

Visual analogue scales (VAS) are employed extensively for pain evaluation, yet it is subjective, but stay valuable instrument for quantifying subjective data, if it is utilised properly. In this study, it showed the exceptional satisfaction of the laser study group to the control counterpart.

Quantification of trismus can be arbitrary, the use of OraStretch[®] ROM scales has simplified this assessment significantly.

Low-level laser therapy (LLLT) has earned considerable recognition [7]. Research have revealed that LLLT amplifies the rate and quality of wound healing and has an inclusive definite impact on the inflammatory processes [8]. Though the published literature on the effects of LLLT on pain in wisdom teeth extraction received mixed results, Bjordal et al's study [9] illustrated that that "0.37-0.96 J/cm² laser had no effect on eliminating symptoms but 6-7 J laser reduced pain to a greater degree". This study employed 4 lots of laser applications each of 4 seconds, and dosage of 1.27 J/cm² at 4 locations buccal, lingual, distal and occlusal aspect of the extraction sites. Total of 2.5 J applied. Therefore, the energy density used in the MLS[®] Mphi exceeded 0.37-0.96 J/cm². The outcome of this study illustrated pain, bleeding, swelling, trismus and speech impairment all were reduced with the use of Mphi laser. This clearly demonstrated that synchronous MLS[®] of Mphi laser did showed the anti-inflammation, anti-edema and analgesic effects in complication of wisdom teeth extraction.

It was discovered that continuous-mode diode Low Level Laser Therapy (LLLT) of

808 nm wavelength enhances speed of wound healing and decreases inflammation contrasted to Alvogyl and SaliCept [10]. This study has demonstrated that Mphi laser help to reduce incidence of dry socket in two female patients ($P > 0.05$). However, due to small sample size, the result did not yield a statistical significance. Certainly, further study with larger sample size is essential for achieving a significant outcome.

In term of overall satisfaction, patients appeared to be more satisfied in the initial phase of the treatment, and not at the later one when the extractions wound were almost healed then satisfaction rate showed to be of no difference.

CONCLUSION

This study showed that application of Mphi laser after wisdom teeth extraction is a least invasive, effective, and innovative technique that can deliver a slightly better early stage satisfaction result as compare to the traditional care approach in impacted wisdom teeth extraction. Use of therapeutic MLS[®] laser rendered less complications such as pain, swelling, bleeding, trismus and speech impairment. VAS and OraStretch[®] ROM scales are good means to quantify the effect of Mphi laser on wisdom teeth extraction complications. Further studies with larger sample sizes are required to validate the measuring outcomes.

ACKNOWLEDGEMENTS

The authors of this paper would like to acknowledge the kindness of ASA Laser Italy for their provision of the MLS[®] Mphi laser used in study. This research is a self-funded and independent project.

REFERENCES

- 1 Fekrazad R, et al. Low Level Laser Therapy in Management of Complications after Intra Oral Surgeries. *Journal of Lasers in Medical Sciences*, 2012. 3(4): 135-140.
- 2 Bennett CA, Olmos SR. Treatment of Chronic Craniofacial Pain with Mphi Laser and Orthotic. *Energy for Health*, 2015; 13: 4-8.
- 3 Lievens PC, Delforge AL. Efficiency of infrared laser treatment examined in the healing of bedsores. *Clin Laser Mon*, 1992, Oct;10(10):159-60.
- 4 Monici M, Cialdai F, Ranaldi F, Paoli P, Boscaro F, Moneti G, Caselli A. Effect of IR laser on myoblasts: a proteomic study. *Mol. BioSyst.* 2013, 9: 1147-1161.
- 5 Doan N, Nguyen M, Du Z, Reher P, Xiao Y, A Measure of Clinical Outcomes in Dental Implant Surgery Flapless Surgery versus Flap Technique in Posterior Maxilla of Post Menopause Women. *The Proceedings of the Fifth International Conference on the Development of Biomedical Engineering in Vietnam from June 16-18, 2014 in Ho Chi Minh City*, 2014: 196-199.
- 6 Sewitch M, Measuring Differences Between Patients' and Physicians' Health Perceptions: The Patient-Physician Discordance Scale *Journal of Behavioral Medicine*. 2003, 26(3): 245-264.
- 7 Ahmed H, Sayed H, Photo-Stimulatory Effect of Low Level Energy Laser Irradiation On The Progress Of Wound Healing In Mice. *Journal of American Science*, 2012;8(12): 203-211.
- 8 Houreld NN, Shedding Light on a New Treatment for Diabetic Wound Healing: A Review on Phototherapy. *The Scientific World Journal*. 2014: (2014), 1-13.
- 9 Bjordal JM, Turner J, Frigo L, Jerde K, et al. A systemic review of postoperative pain relief by low level laser therapy after 3rd molar extraction. *Br J Oral Maxillofacial Surg*, 2007;54:253-6.
- 10 Eshghpour M et al. Comparison of the effect of low level laser therapy with alvogyl on the management of alveolar osteitis. *Med Oral Patol Oral Cir Bucal*, 2015; 20(3): e386-e392.